

FUNCTIONAL VS ORGANIC CONSTIPATION

دکتر محمد سبحانی

دانشیار دانشگاه علوم پزشکی گلستان

نکات طلایی

۱: مدفوع بزرگ و حجیم هیرشپرونگ را رد میکند

۲: فواصل بهبودی در کودک هیرشپرونگ را رد میکند

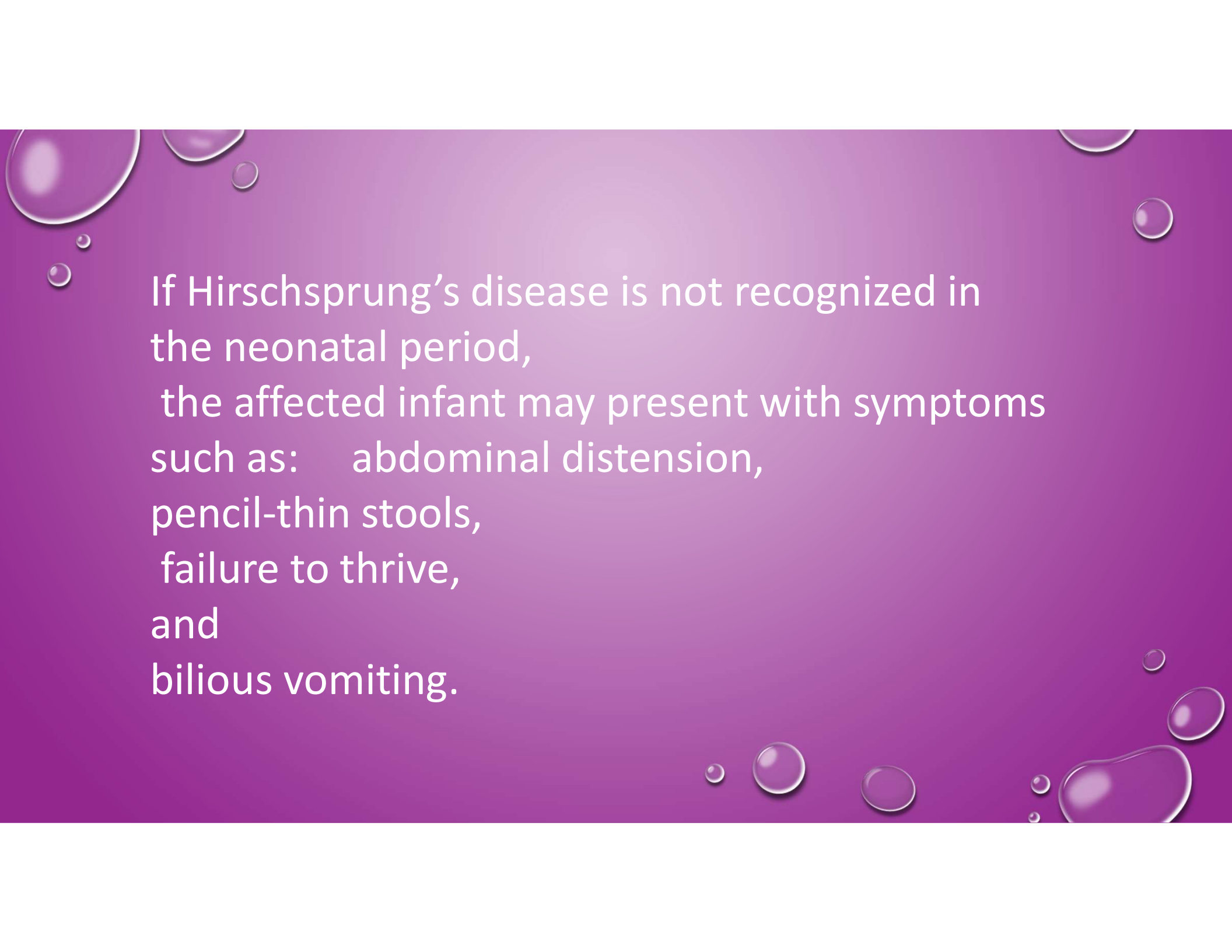
Slide 2

PD1 Persian Digital ۴۰۹/۱۴۰۴ :

Organic causes of constipation most commonly are found in neonates

Failure to pass a meconium stool within 48 hours of birth should raise suspicion for Hirschsprung's disease (congenital aganglionic megacolon).

anatomic position and patency of the anus

The background is a solid purple color with several realistic water droplets of various sizes scattered across it, primarily concentrated in the top-left and bottom-right corners. The droplets have highlights and shadows, giving them a three-dimensional appearance.

If Hirschsprung's disease is not recognized in the neonatal period, the affected infant may present with symptoms such as: abdominal distension, pencil-thin stools, failure to thrive, and bilious vomiting.

The background is a solid purple color with several realistic water droplets of various sizes scattered across it, primarily along the top and bottom edges. The droplets have highlights and shadows, giving them a three-dimensional appearance.

A delay in diagnosing places the infant at risk for :

enterocolitis, with fever, explosive bloody diarrhea, and abdominal distension, in the second or third month of life.

Warning Signs for Organic Causes of Constipation in Infants and Children

Warning signs or symptoms

Passage of meconium more than 48 hours after delivery, small-caliber stools, failure to thrive, fever, bloody diarrhea, bilious vomiting, tight anal sphincter, and empty rectum with palpable abdominal fecal mass

Abdominal distention, bilious vomiting, ileus

Decrease in lower extremity reflexes or muscular tone, absence of anal wink, presence of pilonidal dimple or hair tuft

Fatigue, cold intolerance, bradycardia, poor growth

Polyuria, polydipsia

Diarrhea, rash, failure to thrive, fever, recurrent pneumonia

Diarrhea after wheat is introduced into diet

Abnormal position or appearance of anus on physical examination

Suggested diagnosis

Hirschsprung's disease

Pseudo-obstruction

Spinal cord abnormalities: tethered cord, spinal cord tumor, myelomeningocele

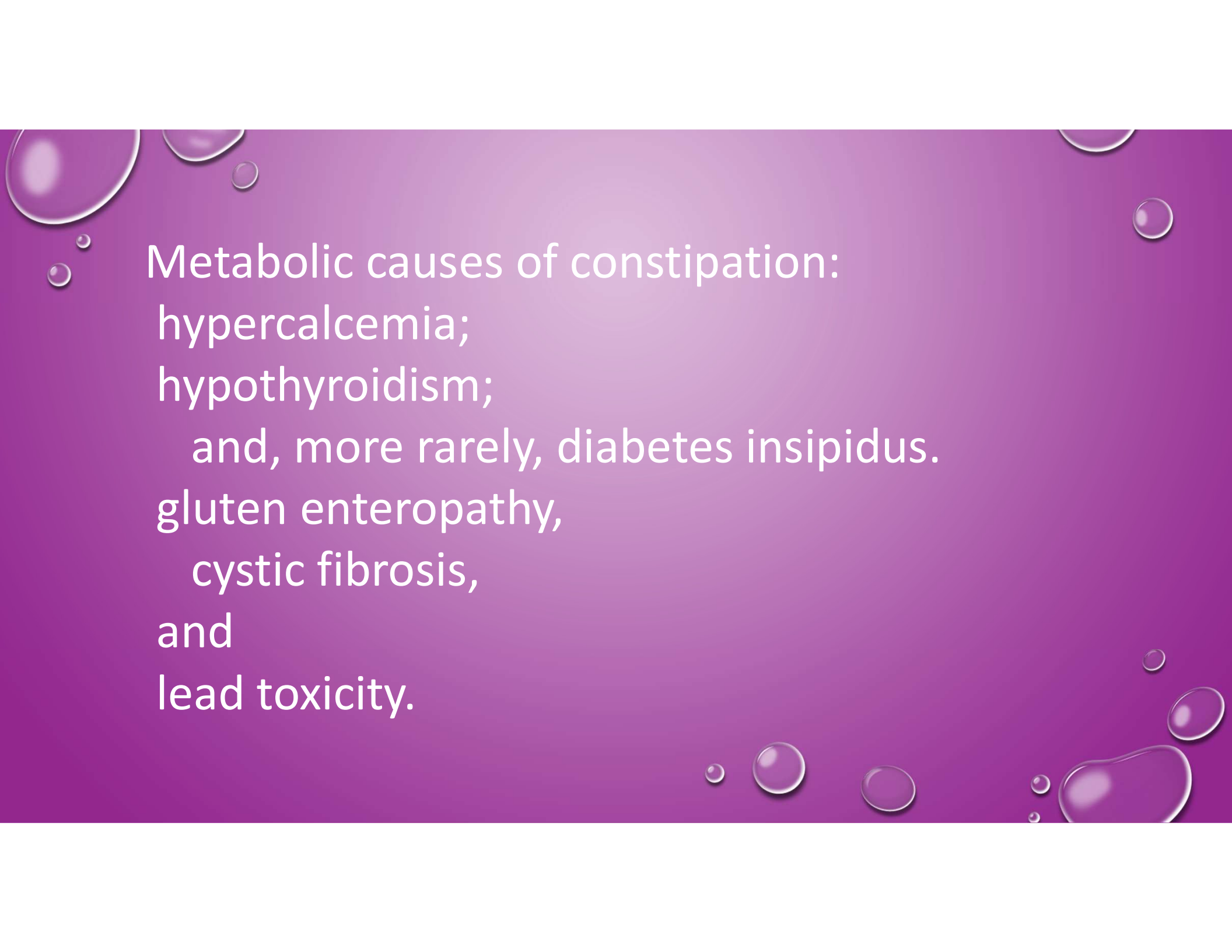
Hypothyroidism

Diabetes insipidus

Cystic fibrosis

Gluten enteropathy

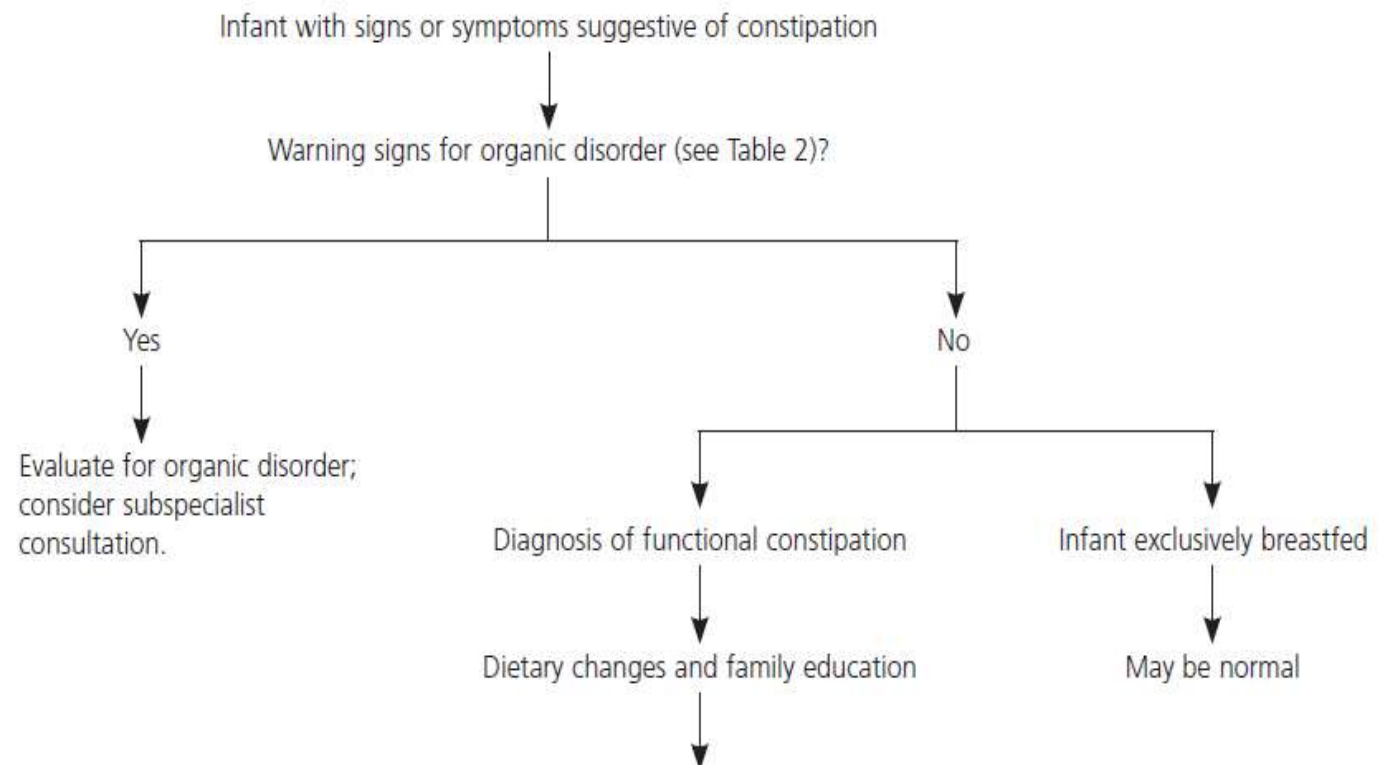
Congenital anorectal malformations: imperforate anus, anal stenosis, anteriorly displaced anus

The background is a solid purple color with several realistic water droplets of various sizes scattered across it, primarily along the top and bottom edges. The droplets have highlights and shadows, giving them a three-dimensional appearance.

Metabolic causes of constipation:
hypercalcemia;
hypothyroidism;
and, more rarely, diabetes insipidus.
gluten enteropathy,
cystic fibrosis,
and
lead toxicity.

- 
- The background is a solid purple color with several realistic water droplets of various sizes scattered across it, primarily along the top and bottom edges. The droplets have highlights and shadows, giving them a three-dimensional appearance.
- Children with developmental or behavioral issues (e.g., mental retardation, autism, oppositional defiant disorder, depression) may be taking constipating medications such as opiates, phenobarbital, and tricyclic antidepressants

Functional Constipation in Infants



زمانهای شایع شروع یبوست فانکشنال

- حوالی ۶ ماهگی
- هنگام از پوشک گرفتن
- ورود به مهد کودک یا مدرسه

Findings Consistent with Functional Constipation

History

Stool passed within 48 hours of birth

Extremely hard stools, large-caliber stools

Fecal soiling (encopresis)

Pain or discomfort with stool passage; withholding of stool

Blood on stools; perianal fissures

Decreased appetite, waxing and waning of abdominal pain with stool passage

Diet low in fiber or fluids, high in dairy products

Hiding while defecating before toilet training is completed; avoiding the toilet

Physical examination

Mild abdominal distention; palpable stool in left lower quadrant

Normal placement of anus; normal anal sphincter tone

Rectum packed with stool; rectum distended

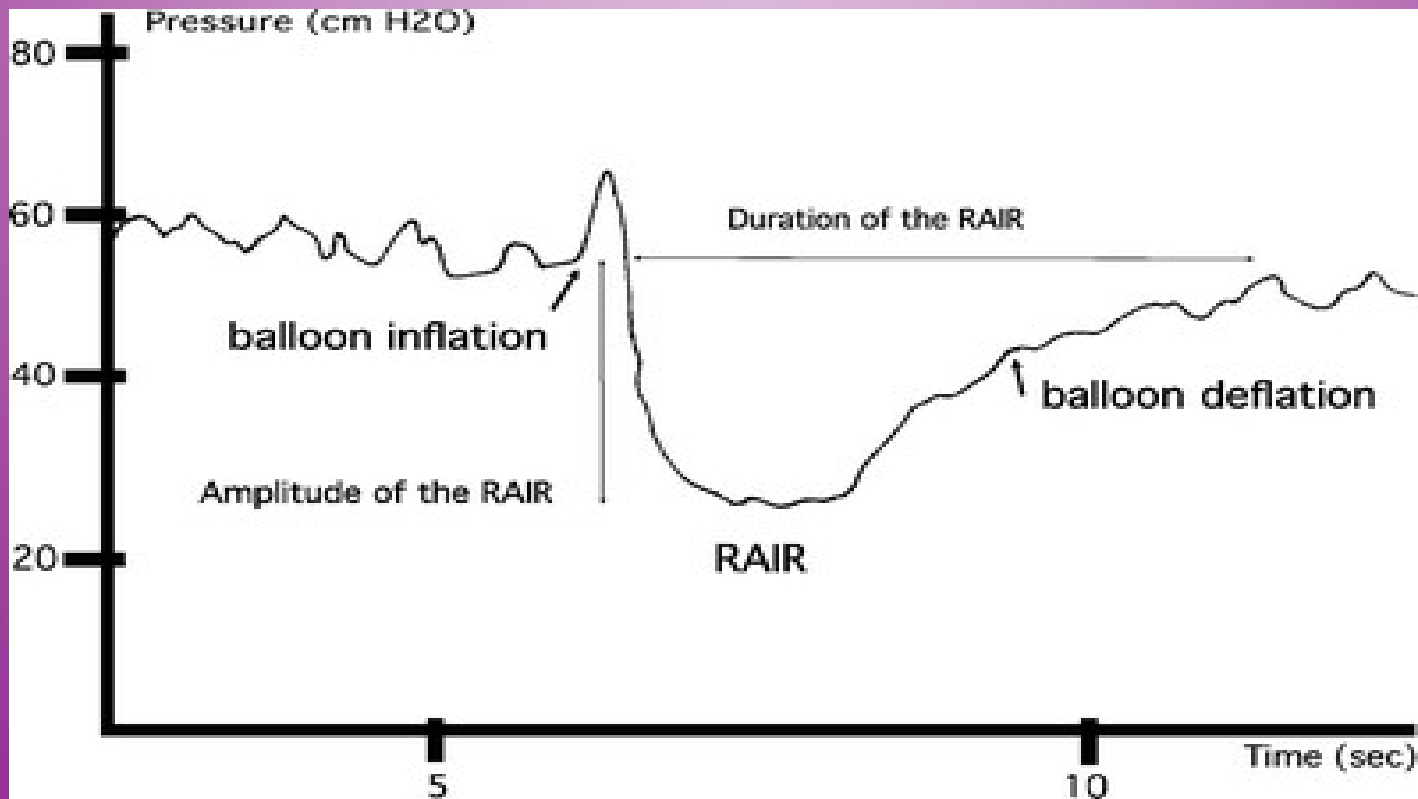
Presence of anal wink and cremasteric reflex

Short-segment Hirschsprung's disease
may remain: **undiagnosed** until a
child is older than three years

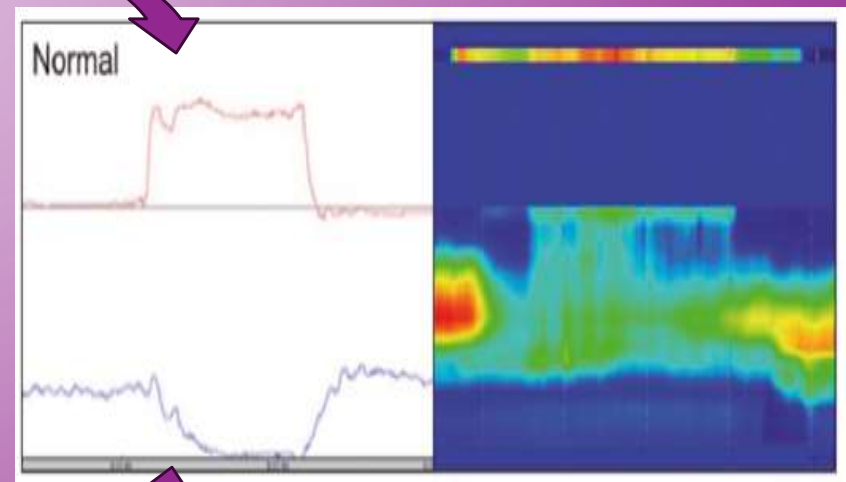
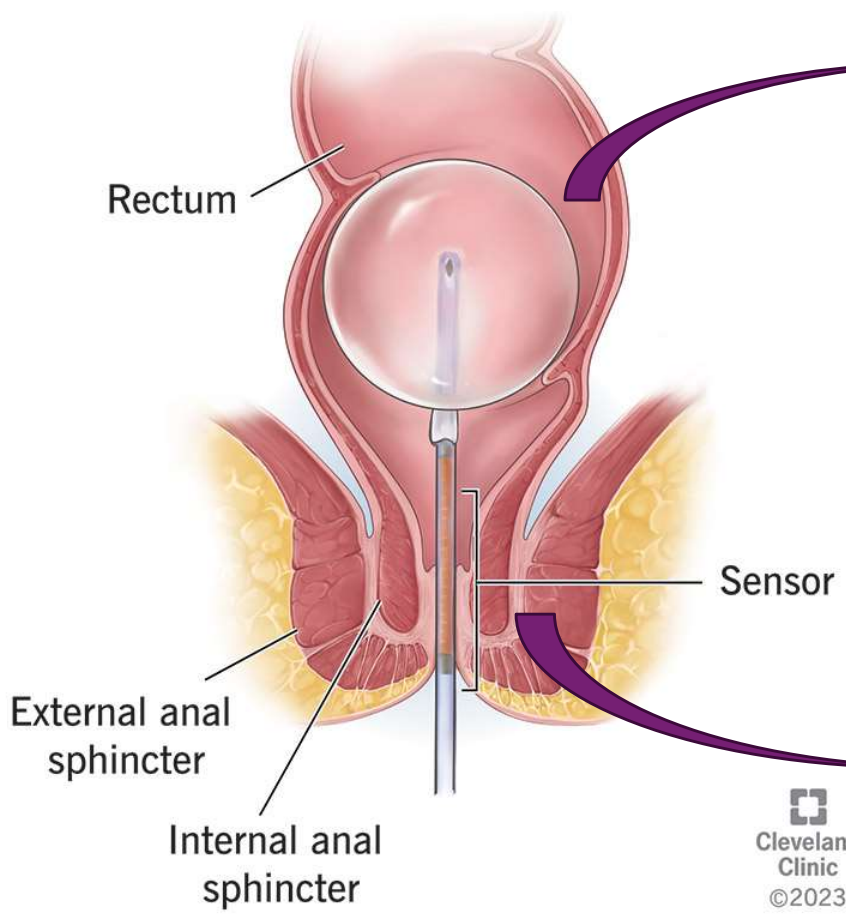
اولتراشورت هیرشپرونگ

- علایم مشابه یبوست فانکشنال است و به درمان جواب نمیدهد
- نیاز به مانومتری دارد

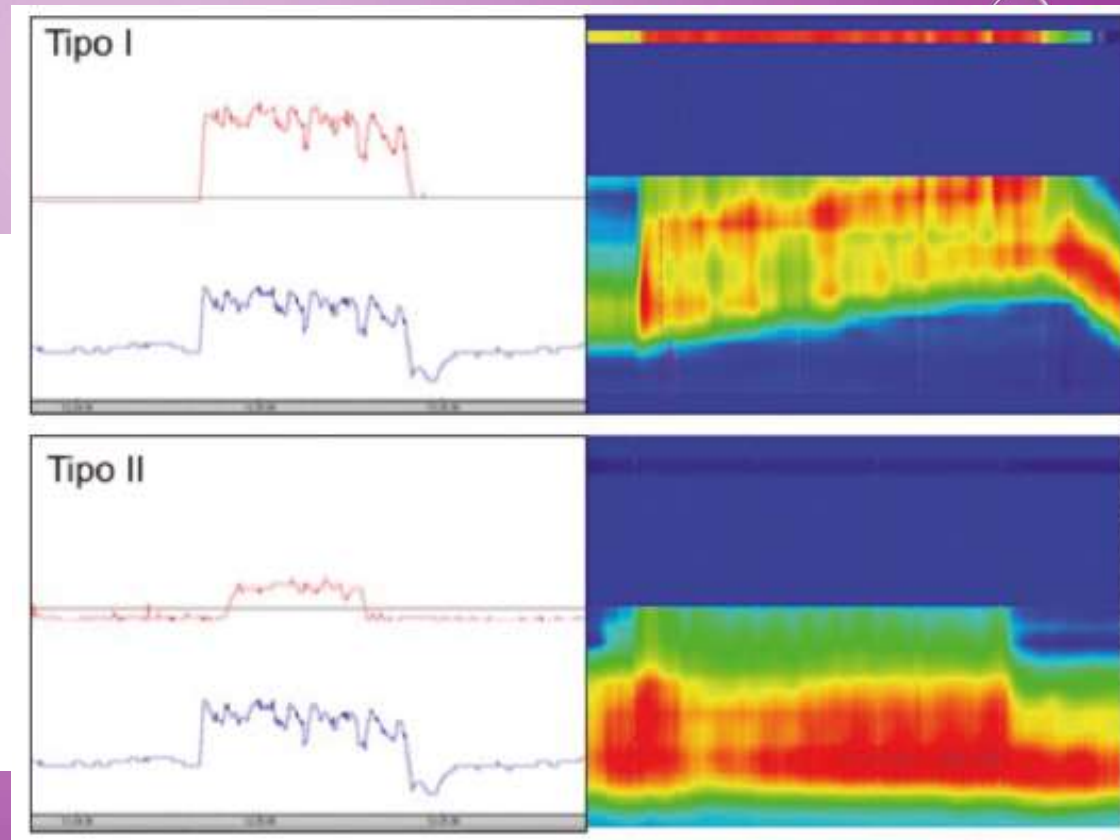
RAIR



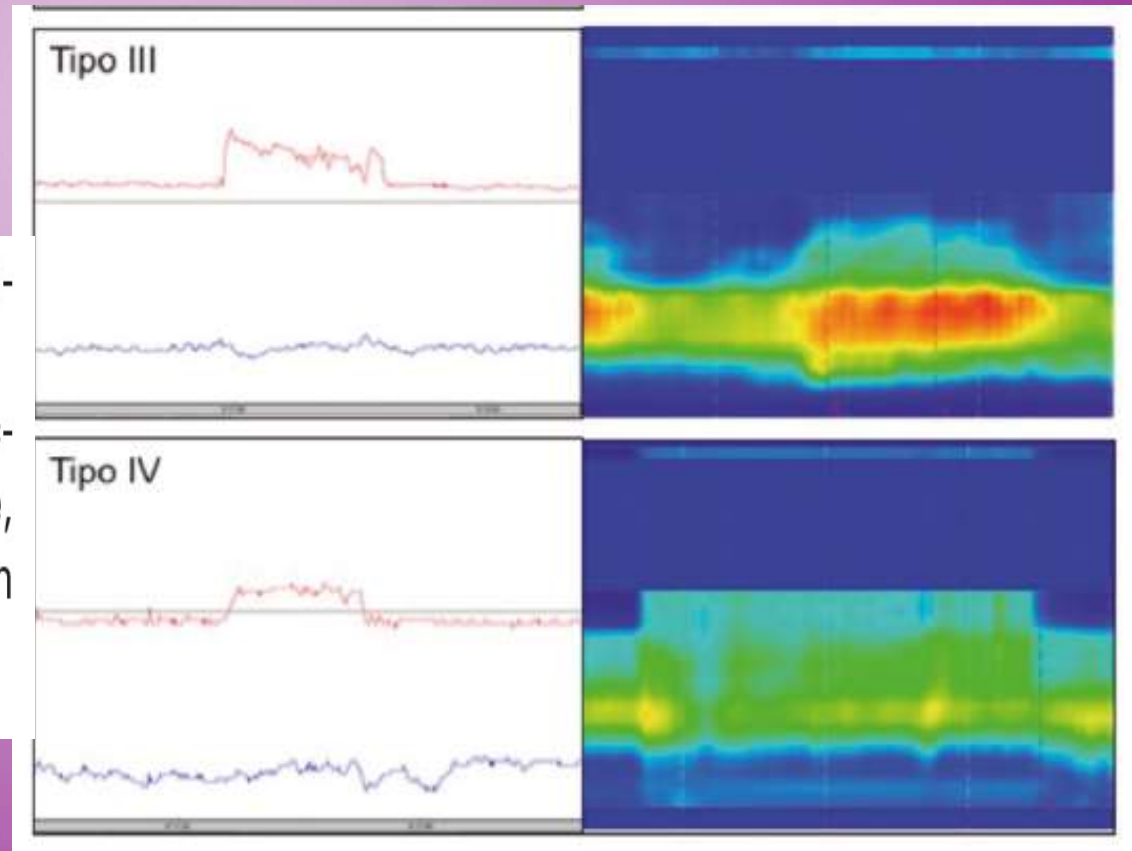
Anorectal manometry



- Type I: adequate propulsive forces (intrarectal pressure > 45 mmHg) but with increase in anal pressure.
- Type II: inability to generate adequate expulsive forces (intrarectal pressure < 45 mmHg) together with paradoxical increase in residual intra-anal pressure.

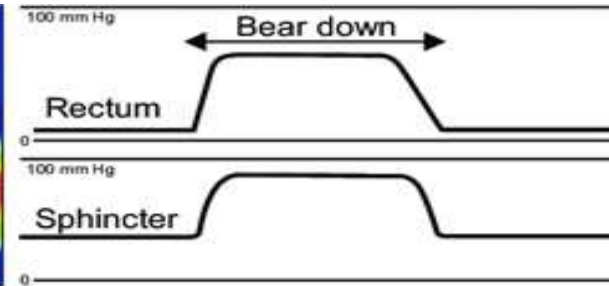
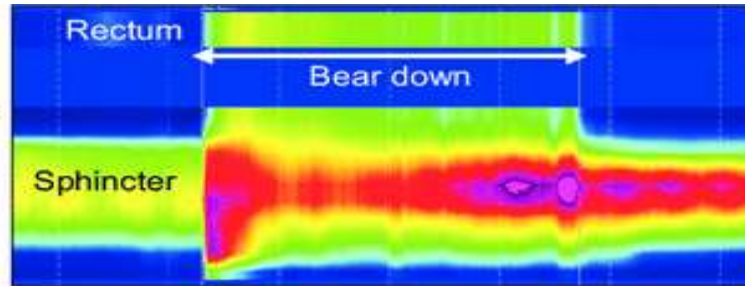


- Type III: adequate propulsive forces with absent or inadequate baseline pressure relaxation (< 20%).
- Type IV: inability to generate adequate expulsive forces, that is, without increase in intrarectal pressure, and absent or inadequate baseline pressure relaxation (< 20%).



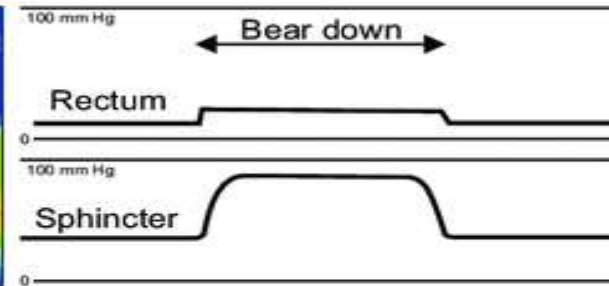
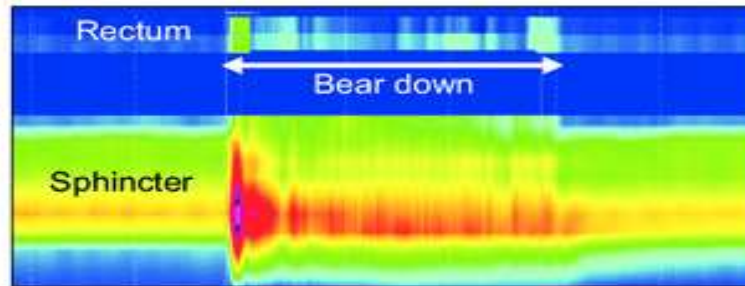
Type I

The patient can generate an adequate pushing force (rise in intra-abdominal pressure) along with a paradoxical increase in anal sphincter pressure.



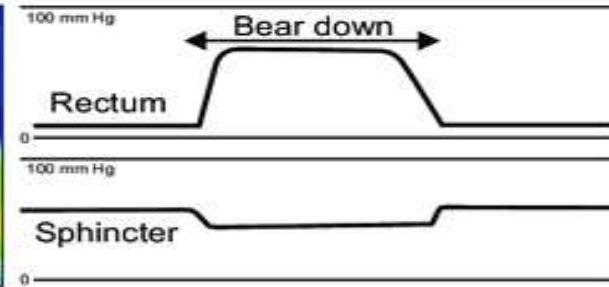
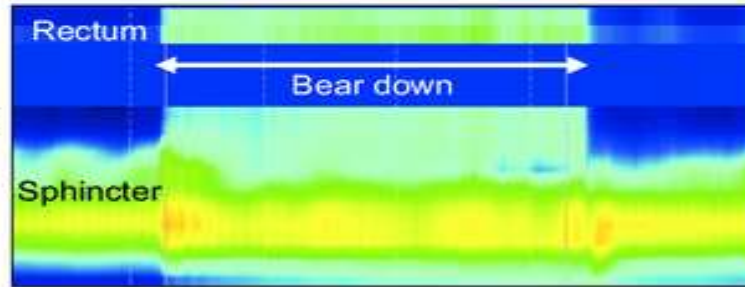
Type II

The patient is unable to generate an adequate pushing force (no increase in intrarectal pressure) but can exhibit a paradoxical anal contraction.



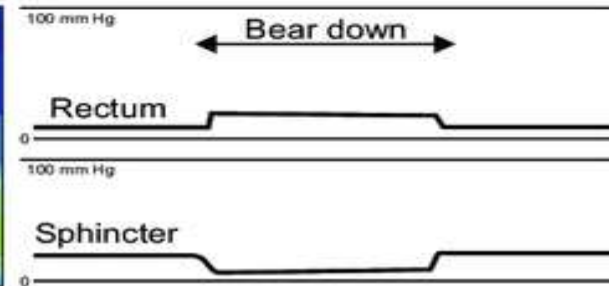

Type III

The patient can generate an adequate pushing force (increase in intrarectal pressure) but, either has absent or incomplete (<20%) sphincter relaxation (i.e., no decrease in anal sphincter pressure).



Type IV

The patient is unable to generate an adequate pushing force and demonstrates an absent or incomplete anal sphincter relaxation.



Types I and III are classically described as: pelvic floor dyssynergia, whereas types II and IV involve: inadequate defecatory propulsion.



خسته نباشید